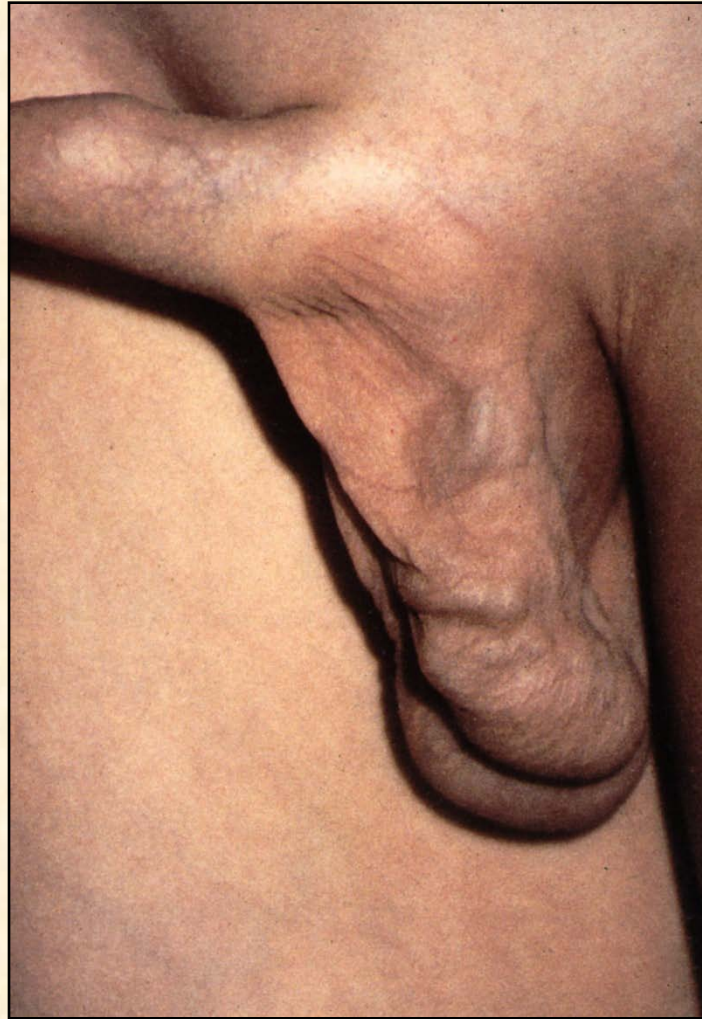

Varicocele

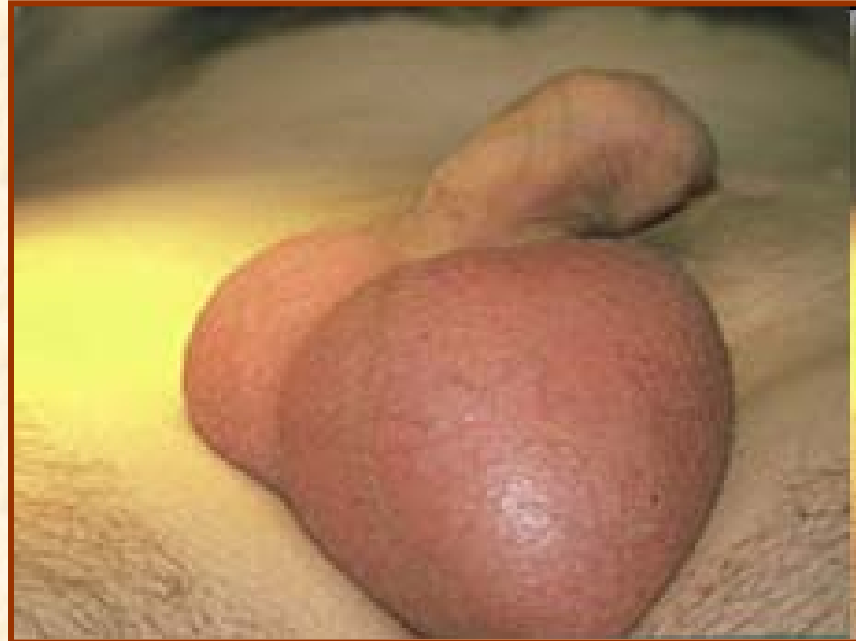CAPITOLO 5
Iconografie
Varie
Patologie
di
Genitali
Maschili



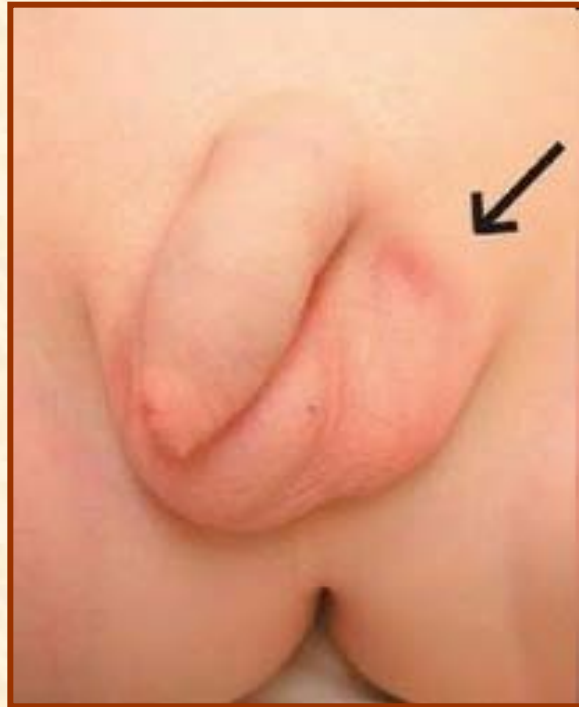
Ipospadia

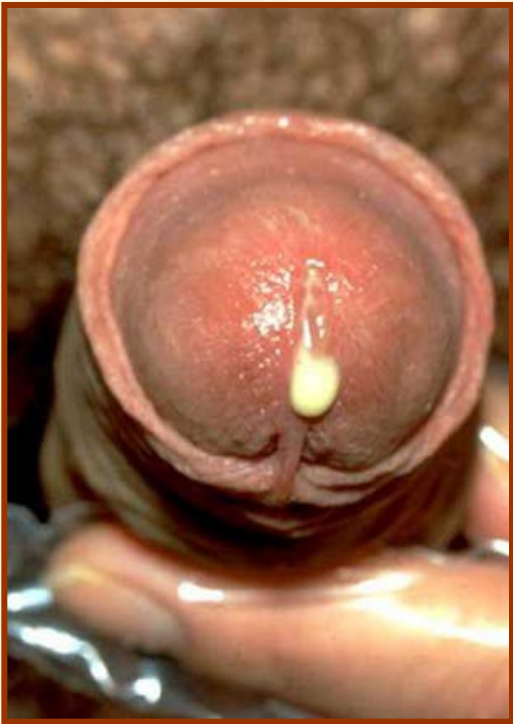

Idrocele

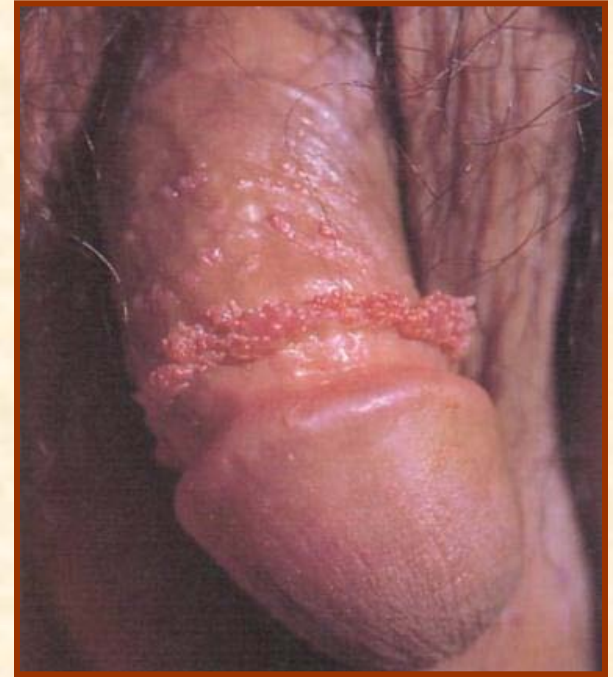

Criptorchidismo

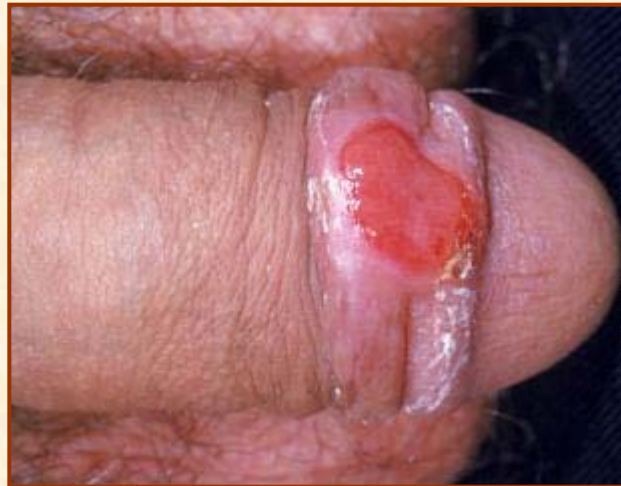



Uretrite



Condilomi da HPV



Sifilide

